

# Chronic spontaneous urticaria: latest developments in aetiology, diagnosis and therapy

Christian Vestergaard and Mette Deleuran

*Ther Adv Chronic Dis*

2015, Vol. 6(6) 304–313

DOI: 10.1177/  
2040622315603951

© The Author(s), 2015.  
Reprints and permissions:  
[http://www.sagepub.co.uk/  
journalsPermissions.nav](http://www.sagepub.co.uk/journalsPermissions.nav)

**Abstract:** Chronic urticaria is a debilitating disease characterized by itching and hives with or without angioedema lasting for more than 6 weeks. The disease carries a significant emotional and economic burden for the patient and often results in an odyssey between doctors of different specialities. Patients suffering from chronic urticaria are considered more difficult to satisfy, treat and to have a bigger emotional burden than the average patient in dermatology, paediatric and general practice settings. A joint initiative under the Dermatology section of the European Academy of Allergy and Clinical immunology (EAACI), the Global Allergy and Asthma European Network (GA<sup>2</sup>LEN), the European Dermatology Forum (EDF) and the World Allergy Organization (WAO) has resulted in recently published guidelines for the diagnosis, classification and treatment of chronic urticarial: these guidelines are clinically useful and have a high success rate when followed in daily clinical practice. The treatment of choice for chronic urticaria is still nonsedating antihistamines although other treatments are available, with omalizumab (humanized IgG anti IgE antibodies) as the newest therapy. The pathogenesis of urticaria is poorly understood but autoimmunity is considered as one of the major underlying causes for this disease, although other theories exist.

**Keywords:** Chronic Urticaria, Diagnosis, treatment

## Diagnosis and classification of urticaria

Urticaria is per definition the appearance of wheals and/or angioedema. However, as described in the following, there are many other diseases presenting with wheals and angioedema that are not chronic urticaria, e.g. allergic anaphylaxis. Wheals are characterized by three features: (1) swelling and erythema, (2) itching/burning sensation and (3) transient nature with the skin returning to normal within 1–24 hours.

According to the European Academy of Allergy and Clinical immunology (EAACI), the Global Allergy and Asthma European Network (GA<sup>2</sup>LEN), the European Dermatology Forum (EDF) and the World Allergy Organization (WAO) guidelines [Zuberbier *et al.* 2014], which are the internationally accepted guidelines, urticaria can be classified according to duration and cause. Acute urticaria is defined as the occurrence of spontaneous wheals with or without angioedema for less than 6 weeks, whereas chronic

urticaria is occurrence of hives with or without angioedema for 6 weeks or more.

Chronic urticaria is classified according to whether it is inducible or not into chronic spontaneous urticaria or chronic inducible urticaria. Chronic spontaneous urticaria may be due to known (e.g. autoantibodies) or unknown causes. The inducible urticarias include cold urticaria, delayed pressure urticaria, solar urticaria, heat urticaria, vibratory urticaria, cholinergic urticaria, contact urticaria, and aquagenic urticaria. A patient may well have more than one type of urticaria. Most of the conditions mentioned are mainly mediated by histamine (Table 1).

## *Wheals and angioedema are not always urticaria*

Type I allergies should be suspected from a thorough history that reveals consistent appearance of wheals or angioedema after ingestion/

Correspondence to:  
**Christian Vestergaard, MD, PhD, DMSc**  
Department of Dermatology,  
Aarhus University Hospital,  
Aarhus, Denmark  
[chr-vest@post9.tele.dk](mailto:chr-vest@post9.tele.dk)  
**Mette Deleuran, MD, DMSc**  
Department of  
Dermatology, Aarhus  
University Hospital,  
Aarhus, Denmark

**Table 1.** Subtypes of chronic urticaria according to European Academy of Allergy and Clinical immunology (EAACI), the Global Allergy and Asthma European Network (GA<sup>2</sup>LEN), the European Dermatology Forum (EDF) and the World Allergy Organization (WAO) [Zuberbier *et al.* 2014].

Chronic urticaria subtypes	
Chronic spontaneous urticaria	Chronic inducible urticaria
Spontaneous urticaria and/or angioedema for more than 6 weeks without known cause	Symptomatic urticarial dermographism, cold urticaria, pressure urticaria, solar urticaria, cholinergic urticaria, contact urticaria, aquagenic urticaria

inhalation, etc., of a specific allergen. To further elucidate whether a type I allergy is the cause of the disease allergen specific skin-prick test and radioallergosorbent test should be performed and finally, if possible, provocation with the suspected allergen will determine whether an allergy is present [Muraro *et al.* 2014].

Auto-inflammatory conditions characterized by urticarial rashes, fever, increased C-reactive protein (CRP) and erythrocyte sedimentation rate (ESR), and increased neutrophils should be considered when a patient presents with severe treatment refractory urticarial rashes [Krause *et al.* 2012]. Auto-inflammatory diseases masquerading as chronic urticaria includes cryopyrin-associated periodic syndromes (CAPS), caused by a mutation in the NLRP3 gene that encodes part of the NLRP3 inflammasome. These conditions were previously referred to as Familial cold auto-inflammatory syndrome, Muckle–Wells syndrome or Neonatal Onset Multisystem Inflammatory Disease [Aksentijevich *et al.* 2007; Petrilli *et al.* 2007; Krause *et al.* 2012]. Mutations in NLRP12 may also be associated with cold-induced auto-inflammatory syndrome [Borghini *et al.* 2011]. Schnitzlers syndrome is characterized by monoclonal gammopathy (IgM or IgG), symptoms of systemic inflammation, and by urticarial rashes. Schnitzlers syndrome may be a prodrome for mb. Waldenström and this should always be considered [Lipsker, 2010]. Other auto-inflammatory diseases presenting with urticarial rashes include adult-onset Still's disease, systemic-onset juvenile idiopathic arthritis, and Mevalonate kinase deficiency/hyper IgD and periodic fever syndrome [Krause *et al.* 2012].

#### Aetiology and work-up

The standard workup varies among different parts of the world. One thing that is common is that a very thorough history should be taken.

These are from the EAACI guidelines [Zuberbier *et al.* 2014], but the general purpose is to discover whether there are any eliciting factors of urticaria since the simplest treatment of course is elimination of any such factors including food allergies, physical provocation factors, etc. If an eliciting factor is suspected, provocations should be performed, e.g. double-blinded placebo-controlled food provocation, pressure, cold, heat, etc., to determine whether it is indeed an eliciting factor. If no symptom-inducing factor can be identified, only differential blood count and CRP or ESR is recommended since chronic or recurrent infections are known to induce urticaria [Zuberbier *et al.* 2014]. Any other tests should only be performed if the history of the patient's symptoms and signs indicate this. Autoimmunity in the pathogenesis of urticaria is still a highly debated topic [Stitt and Dreskin, 2013]. The autologous skin serum test (ASST) and the histamine-release assay are at the moment the only available tests for autoimmunity and even though they correlate with both each other and activity in urticaria symptoms they do not always yield identical results and are not diagnostic for autoimmune urticaria [Platzer *et al.* 2005]. Although not validated, the basophil activation test (BAT) may also turn out to have some diagnostic value in the diagnosis of chronic spontaneous urticaria [Christensen *et al.* 2013].

Patients presenting with wheals lasting for more than 24 hours should be investigated thoroughly for urticarial vasculitis; however, biopsy should be considered even if the wheals are present for less than 24 hours. In a study of 312 patients, 47 histologically had urticarial vasculitis and of these 81% had extracutaneous symptoms [Tosoni *et al.* 2009].

#### Treatment guideline

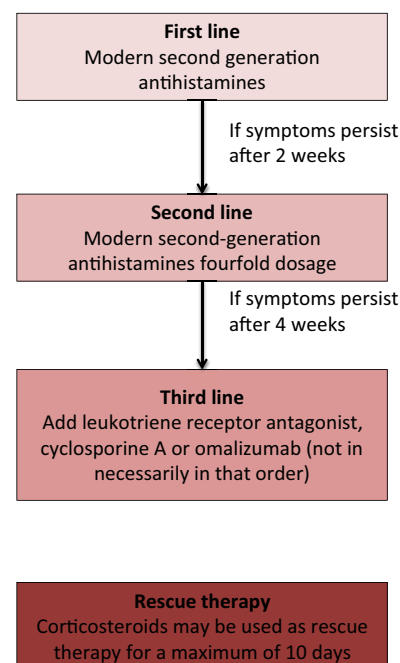
Several drugs have been implicated in the treatment of chronic urticaria with evidence ranging

from randomized double-blind placebo-controlled clinical investigations to anecdotal case reports. In order to establish a firm treatment guide, an initiative under the EAACI/GA<sup>2</sup>LEN/EDF/WAO, using a modified version of the Grading of Recommendations Assessment Development and Evaluation (GRADE) methodology, led to a consensus conference in 2012 at which guidelines on the diagnosis and treatment of urticaria, first published in 2006, were updated for the third version [Zuberbier *et al.* 2014]. The newest guidelines recommend a stepwise approach to the pharmacological treatment of chronic urticaria. First-line therapy is nonsedating antihistamines and if symptoms persist for more than 2 weeks, up dosing to fourfold the normal dose is recommended. If the symptoms persist for more than 4 weeks the guidelines recommend addition of omalizumab, cyclosporine A or montelukast (not in any preferred order) (Figure 1). Other therapeutic options, which have not been included in the guideline, are dapson, anticoagulants, methotrexate, azathioprine, mycophenolate mofetil and biologics including intravenous immunoglobulins (IVIGs), rituximab, and adalimumab.

#### Nonsedating antihistamines

The majority of the symptoms seen in chronic urticaria are mediated by the H1-histamine receptor located on the endothelial cells of the vessels and nerve fibres. Antihistamines are inverse receptor agonists that stabilize the inactive conformation of the H1-receptor and interfere with the action of histamine [Church *et al.* 2010].

The effect of second-generation antihistamines in the treatment of chronic spontaneous urticaria has been examined in several double-blind placebo-controlled randomized trials and is unquestionably the best-documented effective treatment for urticaria. Currently, it is not possible to make a recommendation of which second-generation antihistamine to use. Only a few studies comparing antihistamines exist, and only for the relatively new antihistamine ebastine, which, when compared to fexofenadine and desloratidine has comparable effects and side effects [Barbanoj *et al.* 2003; Antonijoan *et al.* 2007]. If the effect of the recommended dose of the antihistamine is not sufficient, studies on bilastine, cetirizine, desloratidine, levocetirizine, rupatidine and fexofenadine have shown that up dosing to fourfold dosage is an effective and safe strategy [Kontou-Fili *et al.* 1989; Zuberbier *et al.* 1996;



**Figure 1.** Chronic urticaria treatment guideline according to the European Academy of Allergy and Clinical Immunology (EAACI), the Global Allergy and Asthma European Network (GA<sup>2</sup>LEN), the European Dermatology Forum (EDF) and the World Allergy Organization (WAO) [Zuberbier *et al.* 2014].

Gimenez-Arnau *et al.* 2009; Siebenhaar *et al.* 2009; Staevska *et al.* 2010].

First-generation antihistamines are equally efficient in the relief of symptoms: it is however not recommended to use these due to their sedating effects which damage sleep quality by reduced and delayed rapid eye movement (REM) sleep, but also due to a ‘hangover’ effect with impaired cognitive functions up to 24 hours after use, with learning disabilities and loss of productivity as a consequence [Church *et al.* 2010].

#### Leukotriene receptor antagonists

If there is insufficient effect of treatment with nonsedating antihistamines in fourfold the recommended dose, one of the treatments recommended in the guidelines is addition of leukotriene receptor antagonists (LTRAs). These include montelukast, zafirlukast and pranlukast that block the leukotriene receptors for the cysteinyl leukotrienes, which are potent inflammatory mediators. The LTRAs are registered for the treatment of asthma and allergic rhinitis, yet their role in the treatment of chronic urticaria is still debated, as there are

contradictory results on their use. One randomized placebo-controlled study including 160 adult patients showed that the LTRA, montelukast, was superior to placebo in controlling symptoms whereas there was no significant difference when comparing the results of treatment with desloratidine and desloratidine combined with montelukast. Treatment with desloratidine in this study was superior in effect to treatment with montelukast only [Di Lorenzo *et al.* 2004]. Another randomized double-blind placebo-controlled study included 81 patients treated with desloratidine, desloratidine plus montelukast or placebo. In this study, the desloratidine plus montelukast combination showed better effect in controlling symptoms than desloratidine alone [Nettis *et al.* 2004]. Several smaller studies [Erbagci, 2002; Reimers *et al.* 2002; Bagenstose *et al.* 2004; Godse, 2006; Agcaoili *et al.* 2011; Kosnik and Subic, 2011] have been performed and taken together they favour the use of LTRAs together with antihistamines rather than antihistamines alone, whereas antihistamines alone are better than LTRAs alone as reviewed by De Silva and colleagues [De Silva *et al.* 2014].

#### Cyclosporine A

Cyclosporine A inhibits calcineurin, which dephosphorylates the cytoplasmic form of NF-ATc (cytoplasmic form of nuclear factor of T cell) resulting in activation and relocation to the nucleus, NF-ATn, where it controls the transcription of, for example, inflammatory cytokines. In a randomized placebo-controlled study, 30 patients suffering from antihistamine-resistant chronic urticaria, and with a positive ASST were randomized 2:1 to either cyclosporine A (4 mg kg<sup>-1</sup>) or placebo both as add-on with antihistamines [Grattan *et al.* 2000]. In another randomized double-blind placebo-controlled study of 99 patients suffering from chronic spontaneous urticarial, patients were treated with cyclosporine A (3 mg kg<sup>-1</sup>) for 16 weeks, or for 8 weeks followed by 8 weeks of placebo or 16 weeks with placebo only. These studies showed a response rate between 53% and 70% compared with the placebo group [Vena *et al.* 2006].

Prospective open-label studies of cyclosporine A in doses ranging from 2.5 to 8 mg kg<sup>-1</sup> with a total of 258 patients included showed a very variable response rate from 13% to 100%. Unfortunately outcome measures were not consistent, but taken together cyclosporine A does have a place in the treatment of urticaria although its nephrotoxicity

should be given serious consideration before starting treatment [Toubi *et al.* 1997; Ilter *et al.* 1999; Loria *et al.* 2001; Di Gioacchino *et al.* 2003; Baskan *et al.* 2004; Serhat Inaloz *et al.* 2008; Ohtsuka, 2010; Boubouka *et al.* 2011].

Taken together there is good evidence for using cyclosporine A in the treatment of chronic spontaneous urticaria, although with proper surveillance of the potential side effects of this treatment with regular screening of haematological parameters and decreased kidney and liver function.

#### Omalizumab

Omalizumab is a humanized IgG-anti-IgE antibody, which binds human IgE and inhibits its binding to the FcεR-1. It was primarily registered for the use in the treatment of allergic asthma, but has been shown to be very effective in the treatment of chronic urticaria.

The effect of omalizumab on chronic spontaneous urticaria with or without angioedema has been demonstrated in several double-blinded randomized placebo-controlled studies, including almost 1200 patients [Maurer *et al.* 2011; Maurer 2011a; Saini *et al.* 2011; Kaplan *et al.* 2013; Maurer *et al.* 2013; Saini *et al.* 2015]. Dosages range between 75 and 600 mg with active treatment for up to 24 weeks. All dosages show a significant effect on urticaria symptoms, with 300 mg every 4 weeks as the most effective dose on several symptoms including itch, number of hives, angioedema and quality of life. Use of antihistamines was also reduced. Complete resolution of symptoms was achieved in 34–44% of the patients, and almost complete or complete resolution of the symptoms was seen in 52–66% of patients when treated with 300 mg every 4 weeks. Side effects of treatment with omalizumab were comparable with placebo, although a tendency to an increased number of cases with headaches, upper respiratory tract infections, arthralgia and irritation at the site of injection was observed.

Retrospective studies of the effect of omalizumab on chronic spontaneous urticaria also demonstrate the effectiveness of omalizumab. In one study of 51 patients, treatment with omalizumab (300 mg every 4 weeks) resulted in total resolution of the symptoms in 83% of the patients suffering from chronic spontaneous urticaria and in 73% of the patients suffering from chronic

inducible urticaria [Metz *et al.* 2014] whereas a prospective cohort study of 61 patients showed complete resolution in 80% of the patients with chronic spontaneous urticaria. A retrospective case-series study on 17 patients has also showed that omalizumab is effective over a period of at least 4 years [Lefevre *et al.* 2013], whereas another case-series study has shown that omalizumab treatment may be paused and reinstated without loss of effect [Sussman *et al.* 2014].

Although omalizumab is registered at 300 mg every 4 weeks as the dosage for chronic spontaneous urticarial, there is also an effect at 150 mg every 4 weeks in some patients and in some cases dosage needs to be increased to 300 mg every 2 weeks in order to achieve effect. One paper has suggested an algorithm for up dosing and tapering of omalizumab when used for the treatment of chronic spontaneous urticaria. According to this algorithm omalizumab is started at 150 mg, symptoms are assessed after 2 weeks and dosage is either increased or continued. Every 4th week symptoms are re-evaluated and if the patient is symptom free the interval between injections is increased up to 7 weeks after which treatment is stopped [Uysal *et al.* 2014].

Omalizumab is also reported to be effective in treatment of other urticaria forms such as cold urticaria, solar urticaria, cholinergic urticaria and symptomatic urticaria factitia. In addition, omalizumab has also shown effect on the symptoms of indolent systemic mastocytosis [Boyce, 2006; Guzelbey *et al.* 2008; Metz *et al.* 2008; Bindsvle-Jensen and Skov, 2010; Krause *et al.* 2010; Kibsgaard *et al.* 2014; Kibsgaard b.

In summary, omalizumab is the latest development in the treatment of urticaria and offers an efficient and, from high quality studies, scientifically well-established and safe treatment, with relatively few side effects.

#### *Methotrexate*

Methotrexate is an anti-metabolite with anti-proliferative and anti-inflammatory properties. A few case reports have shown effect of this drug in the treatment of chronic urticaria [Weiner, 1989; Gach *et al.* 2001], and a small retrospective study of 16 patients showed effect in 12 cases [Perez *et al.* 2010] whereas a randomized double-blind placebo controlled study with 29 patients showed

no effect of the use of methotrexate [Sharma *et al.* 2014]. Thus methotrexate is in general not recommended for the treatment of chronic spontaneous urticaria, although it may be useful in the treatment of urticarial vasculitis [Morgan and Khan, 2008].

#### *Azathioprine and mycophenolate mofetil*

Azathioprine is a prodrug which together with its metabolites inhibits the function of the lymphocytes through suppression of the purine nucleotide synthesis and through induction of apoptosis of T cells [Sanderson *et al.* 2004]. It is a widely used drug in inflammatory skin diseases, but reported use in chronic spontaneous urticaria has been limited to a few cases and a case-series study [Kibsgaard *et al.* 2014; Kibsgaard b; Tal *et al.* 2015], whereas in urticarial vasculitis it has been used more widely [Venzor *et al.* 2002; Carlson *et al.* 2006; Breda *et al.* 2013].

Mycophenolate mofetil is another purine synthesis inhibitor, which has been reported to be effective in chronic spontaneous urticaria in case reports [Kibsgaard *et al.* 2014; Kibsgaard b; Raghavendran *et al.* 2014], and in open-label studies [Shahar *et al.* 2006; Zimmerman *et al.* 2012]. In these reports, mycophenolate has resulted in complete resolution of symptoms in some but not all cases.

To summarise, azathioprine and mycophenolate mofetil are alternatives for the treatment of chronic spontaneous urticaria, but is not part of the EAACI guideline.

#### *Dapsone*

Dapsone (4,4'-diaminodiphenylsulfone) is an antibiotic with immunomodulatory properties often used in the treatment of inflammatory dermatological diseases. Dapsone has also been used in the treatment of urticaria although evidence for its efficacy has been scarce [Maurer *et al.* 2011; Maurer b]. In one nonblinded clinical study 65 chronic urticaria patients were treated with dapsone plus antihistamine or dapsone alone. Both groups showed significant reduction in urticaria activity score (UAS) and in a visual analogue score (VAS) of the symptoms compared with baseline but not compared to each other. However there was a significantly more-prolonged effect in the group treated with dapsone at 3 months after the end-of-treatment period [Engin and Ozdemir,

2008]. Another open-label study of 11 patients showed complete response in 9 of 11 patients in response to cetirizine 10 and 25 mg/day dapsone. The last two patients had complete response after increase of dapsone to 50 mg/day [Cassano *et al.* 2005]. Recently, a double-blind placebo-controlled crossover study of the effect of dapsone 100 mg in 22 patients with significant decrease in urticaria activity as measured by VAS, UAS and Itch score was published [Morgan and Khan, 2008]. These studies are limited by their methods and number of patients, but they suggest that dapsone may be an alternative in the treatment of chronic spontaneous urticaria especially if treatment is combined with antihistamines.

#### Other drugs

IVIg has been used in smaller case-series studies, and in case reports. The average dose of IVIg ranges from 0.15 to 2 g/kg/day for 1–3 consecutive days and repeated monthly or until remission, which could be sustained for up to 1 year [Kroiss *et al.* 2000; Klote *et al.* 2005; Pereira *et al.* 2007; Hrabak and Calabria, 2010; Mitzel-Kaoukhov *et al.* 2010]. IVIg has also been used for treatment of solar urticaria and urticarial vasculitis [Watkins *et al.* 2012].

Hydroxychloroquine, an antimalarial drug also used as anti-inflammatory drug in other diseases, has been used for the treatment of urticaria. The evidence for this drug is very low though and only one randomized double-blind placebo-controlled study has been performed. The study included 18 patients treated with 200 mg/day, and showed no significant effect [Reeves *et al.* 2004]. Colchicine has also been tested in a few case-series studies on urticarial vasculitis [Pho *et al.* 2011] and delayed pressure urticaria [Lawlor *et al.* 1989], but without convincing effect.

Sulfasalazine (5-aminosalicylic acid derivative) has anti-inflammatory effects through suppression of leukotrienes, mast cell degranulation and inhibition of B-lymphocyte proliferation. For these reasons sulfasalazine has been used in the treatment of urticaria. However only a case-series study and a few case reports have been published on the use of this drug, and its use in the treatment of chronic spontaneous urticaria is doubtful [Engler *et al.* 1995; Mcgirt *et al.* 2006].

Rituximab, a humanized anti CD-20 antibody has also been reported in a few cases to be

effective in the treatment of chronic spontaneous urticaria [Arkwright, 2009; Chakravarty *et al.* 2011], whereas one other case did not show any effect [Mallipeddi and Grattan, 2007]. Antibodies against tumour necrosis factor alpha (TNF- $\alpha$ ) have also been used in the treatment of chronic spontaneous urticaria but with variable success and only in small numbers [Cooke *et al.* 2015].

#### Monitoring treatment outcome

Both in clinical settings and in study settings, monitoring the outcome of the treatment is important for both the treating physician and the patient. When monitoring a chronic disease such as chronic spontaneous urticaria both disease activity and quality of life of the patient should be recorded, and done in a standardized way in order for studies to be compared. For disease activity, two different outcome measures are used, the UAS over 7 days (UAS7) and the urticaria control test (UCT). The UAS7 is a questionnaire filled in over 7 days where the patient scores the number of hives each day on a three-point scale and the intensity of the itch also on a three-point scale, making the maximum score over 7 days [Saini *et al.* 2011]. The scale is easy to use and has been validated and shown to have a minimal important difference (MID) of 9.5–10.5 [Mathias *et al.* 2012]. The UCT covers four areas over the last 4 weeks, physical symptoms, life quality, adequacy of treatment and total control of disease, all four scores on a scale from 1 to 4 where high score is better than low score and giving a maximum of 16 [Weller *et al.* 2014]. The score has been validated showing that a score of 12 or above signifies disease control. Quality of life can be measured by the CU-Q2oL (Chronic urticaria Quality of Life Questionnaire) which, through 23 questions scored on a five-point Likert scale [Baiardini *et al.* 2005], measures the impact of the disease on the patient's quality of life. These outcome measure can demonstrate the impact of the treatment for the physician but, importantly, also for the patient.

#### Conclusions

Chronic spontaneous urticaria is still an enigmatic disease with regard to its aetiology. There is an efficient, simple and easy to use classification from the EAACI/GA<sup>2</sup>LEN/EDF/WAO guideline. This guideline also includes a simple algorithm for the treatment of chronic spontaneous urticaria. It should be kept in mind, however, that treatments not mentioned in the guideline may be

of benefit for selected patients and should not be completely abolished although the evidence level for these is low. The group of patients suffering from chronic spontaneous urticaria is diverse, and the palette of treatments should be as well.

### Funding

This research received no specific grant from any funding agency in the public, commercial, or not-for-profit sectors.

### Declaration of conflict of interest statement

PVCV has received honoraria from Novartis, Abbvie and Leo Pharma for lectures, has served on advisory boards for Novartis and Abbvie, and has also been an investigator for the aforementioned.

### References

Agcaoili, M., Sumpaico, M., Aleta, L., Recto, M. and Abong, J. (2011) Montelukast in the treatment of chronic urticaria: a randomized double blind, placebo-controlled study. *Ann Allergy Asthma Immunol* 107: A17–A17.

Aksentijevich, I., Putnam, C., Remmers, E., Mueller, J., Le, J., Kolodner, R. *et al.* (2007) The clinical continuum of cryopyrinopathies: novel cias1 mutations in North American patients and a new cryopyrin model. *Arthritis Rheum* 56: 1273–1285.

Antonijoan, R., Garcia-Gea, C., Puentes, M., Valle, M., Esbri, R., Fortea, J. *et al.* (2007) A comparison of ebastine 10 mg fast-dissolving tablet with oral desloratadine and placebo in inhibiting the cutaneous reaction to histamine in healthy adults. *Clin Drug Invest* 27: 453–461.

Arkwright, P. (2009) Anti-CD20 or anti-IgE therapy for severe chronic autoimmune urticaria. *J Allergy Clin Immunol* 123: 510–511; author reply 511.

Bagenstose, S., Levin, L. and Bernstein, J. (2004) The addition of zafirlukast to cetirizine improves the treatment of chronic urticaria in patients with positive autologous serum skin test results. *J Allergy Clin Immunol* 113: 134–140.

Baiardini, I., Pasquali, M., Braido, F., Fumagalli, F., Guerra, L., Compalati, E. *et al.* (2005) A new tool to evaluate the impact of chronic urticaria on quality of life: chronic urticaria quality of life questionnaire (CU-QoL). *Allergy* 60: 1073–1078.

Barbanoj, M., Antonijoan, R., Garcia-Gea, C., Morte, A., Gich, I., Gispert, J. *et al.* (2003) A study comparing the inhibitory effects of single and repeated

oral doses of ebastine and fexofenadine against histamine-induced skin reactivity. *Int Arch Allergy Immunol* 132: 263–267.

Baskan, E., Tunalı, S., Turker, T. and Saricaoglu, H. (2004) Comparison of short- and long-term cyclosporine a therapy in chronic idiopathic urticaria. *J Dermatol Treat* 15: 164–168.

Bindslev-Jensen, C. and Skov, P. (2010) Efficacy of omalizumab in delayed pressure urticaria: a case report. *Allergy* 65: 138–139.

Borghini, S., Tassi, S., Chiesa, S., Caroli, F., Carta, S., Caorsi, R. *et al.* (2011) Clinical presentation and pathogenesis of cold-induced autoinflammatory disease in a family with recurrence of an Nlrp12 mutation. *Arthritis Rheum* 63: 830–839.

Boubouka, C., Charissi, C., Kouimintzis, D., Kalogeromitros, D., Stavropoulos, P. and Katsarou, A. (2011) Treatment of autoimmune urticaria with low-dose cyclosporin A: a one-year follow-up. *Acta Derm Venereol* 91: 50–54.

Boyce, J. (2006) Successful treatment of cold-induced urticaria/anaphylaxis with anti-IgE. *J Allergy Clin Immunol* 117: 1415–1418.

Breda, L., Nozzi, M., Harari, S., Del Torto, M., Lucantoni, M., Scardapane, A. *et al.* (2013) Hypocomplementemic urticarial vasculitis (HUVS) with precocious emphysema responsive to azathioprine. *J Clin Immunol* 33: 891–895.

Carlson, J., Cavaliere, L. and Grant-Kels, J. (2006) Cutaneous vasculitis: diagnosis and management. *Clin Dermatol* 24: 414–429.

Cassano, N., D'argento, V., Filotico, R. and Vena, G. (2005) Low-dose dapsone in chronic idiopathic urticaria: preliminary results of an open study. *Acta Derm Venereol* 85: 254–255.

Chakravarty, S., Yee, A. and Paget, S. (2011) Rituximab successfully treats refractory chronic autoimmune urticaria caused by IgE receptor autoantibodies. *J Allergy Clin Immunol* 128: 1354–1355.

Christensen, C., Vestergaard, C. and Hoffmann, H. (2013) Activation markers CD63 and CD203c are upregulated in chronic urticaria. *Ann Dermatol* 25: 522–523.

Church, M., Maurer, M., Simons, F., Bindslev-Jensen, C., Van Cauwenberge, P., Bousquet, J. *et al.* (2010) Risk of first-generation H(1)-antihistamines: a GA(2)LEN position paper. *Allergy* 65: 459–466.

Cooke, A., Bulkhi, A. and Casale, T. (2015) Role of biologics in intractable urticaria. *Biologics* 9: 25–33.

De Silva, N., Damayanthi, H., Rajapakse, A., Rodrigo, C. and Rajapakse, S. (2014) Leukotriene

- receptor antagonists for chronic urticaria: a systematic review. *Allergy Asthma Clin Immunol* 10: 24.
- Di Gioacchino, M., Di Stefano, F., Cavallucci, E., Verna, N., Ramondo, S., Paolini, F. *et al.* (2003) Treatment of chronic idiopathic urticaria and positive autologous serum skin test with cyclosporine: clinical and immunological evaluation. *Allergy Asthma Proc* 24: 285–290.
- Di Lorenzo, G., Pacor, M., Mansueto, P., Esposito Pellitteri, M., Lo Bianco, C., Ditta, V. *et al.* (2004) Randomized placebo-controlled trial comparing desloratadine and montelukast in monotherapy and desloratadine plus montelukast in combined therapy for chronic idiopathic urticaria. *J Allergy Clin Immunol* 114: 619–625.
- Engin, B. and Ozdemir, M. (2008) Prospective randomized non-blinded clinical trial on the use of dapson plus antihistamine vs. antihistamine in patients with chronic idiopathic urticaria. *J Eur Acad Dermatol Venereol* 22: 481–486.
- Engler, R., Squire, E. and Benson, P. (1995) Chronic sulfasalazine therapy in the treatment of delayed pressure urticaria and angioedema. *Ann Allergy Asthma Immunol* 74: 155–159.
- Erbagci, Z. (2002) The leukotriene receptor antagonist montelukast in the treatment of chronic idiopathic urticaria: a single-blind, placebo-controlled, crossover clinical study. *J Allergy Clin Immunol* 110: 484–488.
- Gach, J., Sabroe, R., Greaves, M. and Black, A. (2001) Methotrexate-responsive chronic idiopathic urticaria: a report of two cases. *Br J Dermatol* 145: 340–343.
- Gimenez-Arnau, A., Izquierdo, I. and Maurer, M. (2009) The use of a responder analysis to identify clinically meaningful differences in chronic urticaria patients following placebo-controlled treatment with rupatadine 10 and 20 mg. *J Eur Acad Dermatol Venereol* 23: 1088–1091.
- Godse, K. (2006) Oral montelukast monotherapy is ineffective in chronic idiopathic urticaria: a comparison with oral cetirizine. *Indian J Dermatol Venereol Leprol* 72: 312–314.
- Grattan, C., O'donnell, B., Francis, D., Niimi, N., Barlow, R., Seed, P. *et al.* (2000) Randomized double-blind study of cyclosporin in chronic 'idiopathic' urticaria. *Br J Dermatol* 143: 365–372.
- Guzelbey, O., Ardelean, E., Magerl, M., Zuberbier, T., Maurer, M. and Metz, M. (2008) Successful treatment of solar urticaria with anti-immunoglobulin E therapy. *Allergy* 63: 1563–1565.
- Hrabak, T. and Calabria, C. (2010) Multiple treatment cycles of high-dose intravenous immunoglobulin for chronic spontaneous urticaria. *Ann Allergy Asthma Immunol* 105: 245; author reply 245–246.
- Ilter, N., Gurer, M. and Akkoca, M. (1999) Short-term oral cyclosporine for chronic idiopathic urticaria. *J Eur Acad Dermatol Venereol* 12: 67–69.
- Kaplan, A., Ledford, D., Ashby, M., Canvin, J., Zazzali, J., Conner, E. *et al.* (2013) Omalizumab in patients with symptomatic chronic idiopathic/spontaneous urticaria despite standard combination therapy. *J Allergy Clin Immunol* 132: 101–109.
- Kibsgaard, L., Lefevre, A., Deleuran, M. and Vestergaard, C. (2014a) A case series study of eighty-five chronic spontaneous urticaria patients referred to a tertiary care center. *Ann Dermatol* 26: 73–78.
- Kibsgaard, L., Skjold, T., Deleuran, M. and Vestergaard, C. (2014b) Omalizumab induced remission of idiopathic anaphylaxis in a patient suffering from indolent systemic mastocytosis. *Acta Derm Venereol* 94: 363–364.
- Klote, M., Nelson, M. and Engler, R. (2005) Autoimmune urticaria response to high-dose intravenous immunoglobulin. *Ann Allergy Asthma Immunol* 94: 307–308.
- Kontou-Fili, K., Paleologos, G. and Herakleous, M. (1989) Suppression of histamine-induced skin reactions by loratadine and cetirizine dihydrochloride. *Eur J Clin Pharmacol* 36: 617–619.
- Kosnik, M. and Subic, T. (2011) Add-on montelukast in antihistamine-resistant chronic idiopathic urticaria. *Respir Med* 105(Suppl. 1): S84–S88.
- Krause, K., Ardelean, E., Kessler, B., Magerl, M., Metz, M., Siebenhaar, F. *et al.* (2010) Antihistamine-resistant urticaria factitia successfully treated with anti-immunoglobulin E therapy. *Allergy* 65: 1494–1495.
- Krause, K., Grattan, C., Bindslev-Jensen, C., Gattorno, M., Kallinich, T., De Koning, H. *et al.* (2012) How not to miss autoimmune inflammatory diseases masquerading as urticaria. *Allergy* 67: 1465–1474.
- Kroiss, M., Vogt, T., Landthaler, M. and Stolz, W. (2000) The effectiveness of low-dose intravenous immunoglobulin in chronic urticaria. *Acta Derm Venereol* 80: 225.
- Lawlor, F., Black, A., Ward, A., Morris, R. and Greaves, M. (1989) Delayed pressure urticaria, objective evaluation of a variable disease using a dermatographometer and assessment of treatment using colchicine. *Br J Dermatol* 120: 403–408.
- Lefevre, A., Deleuran, M. and Vestergaard, C. (2013) A long term case series study of the effect of



- omalizumab on chronic spontaneous urticaria. *Ann Dermatol* 25: 242–245.
- Lipsker, D. (2010) The Schnitzler syndrome. *Orphanet J Rare Dis* 5: 38.
- Loria, M., Dambra, P., D'oronzo, L., Nettis, E., Pannofino, A., Cavallo, E. *et al.* (2001) Cyclosporin a in patients affected by chronic idiopathic urticaria: a therapeutic alternative. *Immunopharmacol Immunotoxicol* 23: 205–213.
- Mallipeddi, R. and Grattan, C. (2007) Lack of response of severe steroid-dependent chronic urticaria to rituximab. *Clin Exp Dermatol* 32: 333–334.
- Mathias, S., Crosby, R., Zazzali, J., Maurer, M. and Saini, S. (2012) Evaluating the minimally important difference of the urticaria activity score and other measures of disease activity in patients with chronic idiopathic urticaria. *Ann Allergy Asthma Immunol* 108: 20–24.
- Maurer, M., Altrichter, S., Bieber, T., Biedermann, T., Brautigam, M., Seyfried, S. *et al.* (2011a) Efficacy and safety of omalizumab in patients with chronic urticaria who exhibit IgE against thyroperoxidase. *J Allergy Clin Immunol* 128: 202–209; e205.
- Maurer, M., Rosen, K., Hsieh, H., Saini, S., Grattan, C., Gimenez-Arnau, A. *et al.* (2013) Omalizumab for the treatment of chronic idiopathic or spontaneous urticaria. *N Engl J Med* 368: 924–935.
- Maurer, M., Weller, K., Bindslev-Jensen, C., Gimenez-Arnau, A., Bousquet, P., Bousquet, J. *et al.* (2011b) Unmet clinical needs in chronic spontaneous urticaria. A GA(2)LEN task force report. *Allergy* 66: 317–330.
- Mcgirt, L., Vasagar, K., Gober, L., Saini, S. and Beck, L. (2006) Successful treatment of recalcitrant chronic idiopathic urticaria with sulfasalazine. *Arch Dermatol* 142: 1337–1342.
- Metz, M., Bergmann, P., Zuberbier, T. and Maurer, M. (2008) Successful treatment of cholinergic urticaria with anti-immunoglobulin E therapy. *Allergy* 63: 247–249.
- Metz, M., Ohanyan, T., Church, M. and Maurer, M. (2014) Omalizumab is an effective and rapidly acting therapy in difficult-to-treat chronic urticaria: a retrospective clinical analysis. *J Dermatol Sci* 73: 57–62.
- Mitzel-Kaoukhov, H., Staubach, P. and Muller-Brenne, T. (2010) Effect of high-dose intravenous immunoglobulin treatment in therapy-resistant chronic spontaneous urticaria. *Ann Allergy Asthma Immunol* 104: 253–258.
- Morgan, M. and Khan, D. (2008) Therapeutic alternatives for chronic urticaria: an evidence-based review, part 2. *Ann Allergy Asthma Immunol* 100: 517–526; quiz 526–518, 544.
- Muraro, A., Werfel, T., Hoffmann-Sommergruber, K., Roberts, G., Beyer, K., Bindslev-Jensen, C. *et al.* (2014) EAACI food allergy and anaphylaxis guidelines: diagnosis and management of food allergy. *Allergy* 69: 1008–1025.
- Nettis, E., Colanardi, M., Paradiso, M. and Ferrannini, A. (2004) Desloratadine in combination with montelukast in the treatment of chronic urticaria: a randomized, double-blind, placebo-controlled study. *Clin Exp Allergy* 34: 1401–1407.
- Ohtsuka, T. (2010) Response to oral cyclosporine therapy and high sensitivity-CRP level in chronic idiopathic urticaria. *Int J Dermatol* 49: 579–584.
- Pereira, C., Tavares, B., Carrapatoso, I., Loureiro, G., Faria, E., Machado, D. *et al.* (2007) Low-dose intravenous gammaglobulin in the treatment of severe autoimmune urticaria. *Eur Ann Allergy Clin Immunol* 39: 237–242.
- Perez, A., Woods, A. and Grattan, C. (2010) Methotrexate: a useful steroid-sparing agent in recalcitrant chronic urticaria. *Br J Dermatol* 162: 191–194.
- Petrilli, V., Dostert, C., Muruve, D. and Tschopp, J. (2007) The inflammasome: a danger sensing complex triggering innate immunity. *Curr Opin Immunol* 19: 615–622.
- Pho, L., Eliason, M., Regruto, M., Hull, C. and Powell, D. (2011) Treatment of chronic urticaria with colchicine. *J Drugs Dermatol* 10: 1423–1428.
- Platzer, M., Grattan, C., Poulsen, L. and Skov, P. (2005) Validation of basophil histamine release against the autologous serum skin test and outcome of serum-induced basophil histamine release studies in a large population of chronic urticaria patients. *Allergy* 60: 1152–1156.
- Raghavendran, R., Humphreys, F. and Kaur, M. (2014) Successful use of mycophenolate mofetil to treat severe chronic urticaria in a patient intolerant to ciclosporin. *Clin Exp Dermatol* 39: 68–69.
- Reeves, G., Boyle, M., Bonfield, J., Dobson, P. and Loewenthal, M. (2004) Impact of hydroxychloroquine therapy on chronic urticaria: chronic autoimmune urticaria study and evaluation. *Intern Med J* 34: 182–186.
- Reimers, A., Pichler, C., Helbling, A., Pichler, W. and Yawalkar, N. (2002) Zafirlukast has no beneficial effects in the treatment of chronic urticaria. *Clin Exp Allergy* 32: 1763–1768.
- Saini, S., Rosen, K., Hsieh, H., Wong, D., Conner, E., Kaplan, A. *et al.* (2011) A randomized, placebo-controlled, dose-ranging study of single-dose omalizumab in patients with H1-antihistamine-refractory chronic idiopathic urticaria. *J Allergy Clin Immunol* 128: 567–573 e561.

- Saini, S., Bindslev-Jensen, C., Maurer, M., Grob, J., Bulbul Baskan, E., Bradley, M. *et al.* (2015) Efficacy and safety of omalizumab in patients with chronic idiopathic/spontaneous urticaria who remain symptomatic on H1 antihistamines: a randomized, placebo-controlled study. *J Invest Dermatol* 135: 925.
- Sanderson, J., Ansari, A., Marinaki, T. and Duley, J. (2004) Thiopurine methyltransferase: should it be measured before commencing thiopurine drug therapy? *Ann Clin Biochem* 41: 294–302.
- Serhat Inaloz, H., Ozturk, S., Akcali, C., Kirtak, N. and Tarakcioglu, M. (2008) Low-dose and short-term cyclosporine treatment in patients with chronic idiopathic urticaria: a clinical and immunological evaluation. *J Dermatol* 35: 276–282.
- Shahar, E., Bergman, R., Guttman-Yassky, E. and Pollack, S. (2006) Treatment of severe chronic idiopathic urticaria with oral mycophenolate mofetil in patients not responding to antihistamines and/or corticosteroids. *Int J Dermatol* 45: 1224–1227.
- Sharma, V., Singh, S., Ramam, M., Kumawat, M. and Kumar, R. (2014) A randomized placebo-controlled double-blind pilot study of methotrexate in the treatment of H1 antihistamine-resistant chronic spontaneous urticaria. *Indian J Dermatol Venereol Leprol* 80: 122–128.
- Siebenhaar, F., Degener, F., Zuberbier, T., Martus, P. and Maurer, M. (2009) High-dose desloratadine decreases wheal volume and improves cold provocation thresholds compared with standard-dose treatment in patients with acquired cold urticaria: a randomized, placebo-controlled, crossover study. *J Allergy Clin Immunol* 123: 672–679.
- Staevska, M., Popov, T., Kralimarkova, T., Lazarova, C., Kraeva, S., Popova, D. *et al.* (2010) The effectiveness of levocetirizine and desloratadine in up to 4 times conventional doses in difficult-to-treat urticaria. *J Allergy Clin Immunol* 125: 676–682.
- Stitt, J. and Dreskin, S. (2013) Urticaria and autoimmunity: where are we now? *Curr Allergy Asthma Rep* 13: 555–562.
- Sussman, G., Hebert, J., Barron, C., Bian, J., Caron-Guay, R., Laflamme, S. *et al.* (2014) Real-life experiences with omalizumab for the treatment of chronic urticaria. *Ann Allergy Asthma Immunol* 112: 170–174.
- Tal, Y., Toker, O., Agmon-Levin, N. and Shalit, M. (2015) Azathioprine as a therapeutic alternative for refractory chronic urticaria. *Int J Dermatol* 54: 367–369.
- Tosoni, C., Lodi-Rizzini, F., Cinquini, M., Pasolini, G., Venturini, M., Sinico, R. *et al.* (2009) A reassessment of diagnostic criteria and treatment of idiopathic urticarial vasculitis: a retrospective study of 47 patients. *Clin Exp Dermatol* 34: 166–170.
- Toubi, E., Blant, A., Kessel, A. and Golan, T. (1997) Low-dose cyclosporin a in the treatment of severe chronic idiopathic urticaria. *Allergy* 52: 312–316.
- Uysal, P., Eller, E., Mortz, C. and Bindslev-Jensen, C. (2014) An algorithm for treating chronic urticaria with omalizumab: dose interval should be individualized. *J Allergy Clin Immunol* 133: 914–915; e912.
- Vena, G., Cassano, N., Colombo, D., Peruzzi, E., Pigatto, P. and Neo, I. (2006) Cyclosporine in chronic idiopathic urticaria: a double-blind, randomized, placebo-controlled trial. *J Am Acad Dermatol* 55: 705–709.
- Venzor, J., Lee, W. and Huston, D. (2002) Urticarial vasculitis. *Clin Rev Allergy Immunol* 23: 201–216.
- Watkins, C., Peiris, E., Saleh, H. and Krishnaswamy, G. (2012) Intravenous immunoglobulin as a potential therapy for refractory urticaria – a review. *Inflamm Allergy Drug Targets* 11: 375–381.
- Weiner, M. (1989) Methotrexate in corticosteroid-resistant urticaria. *Ann Intern Med* 110: 848.
- Weller, K., Groffik, A., Church, M., Hawro, T., Krause, K., Metz, M. *et al.* (2014) Development and validation of the urticaria control test: a patient-reported outcome instrument for assessing urticaria control. *J Allergy Clin Immunol* 133: 1365–1372, 1372 e1361–1366.
- Zimmerman, A., Berger, E., Elmariah, S. and Soter, N. (2012) The use of mycophenolate mofetil for the treatment of autoimmune and chronic idiopathic urticaria: experience in 19 patients. *J Am Acad Dermatol* 66: 767–770.
- Zuberbier, T., Aberer, W., Asero, R., Bindslev-Jensen, C., Brzoza, Z., Canonica, G. *et al.* (2014) The EAACI/GA(2)LEN/EDF/WAO guideline for the definition, classification, diagnosis, and management of urticaria: The 2013 revision and update. *Allergy* 69: 868–887.
- Zuberbier, T., Munzberger, C., Hausteiner, U., Trippas, E., Burtin, B., Mariz, S. *et al.* (1996) Double-blind crossover study of high-dose cetirizine in cholinergic urticaria. *Dermatology* 193: 324–327.